

Medical Journal of Eastern Nepal

Volume 01, Number 01, Issue 01, June 2022, 42-44

Case Report

THE MECHANICAL HEART VALVE TTK CHITRA IS INEXPENSIVE AND OF PROVEN EFFECTIVENESS (WIDELY USED IN INDIA AND THEN IN NEPAL).

Vasanth Kumar,*Umesh Yadav, Awan Kumar, Vijaylakhsmi

Department Of Cardiology, B&C Medical College Teaching Hospital and Research Center, Birtamode, Jhapa, Nepal

Submitted: 10-March-2022 Revised: 17-March-2022 Accept: 20-March-2022

DOI: <https://doi.org/10.3126/mjen.v1i1.45864>

ABSTRACT


TTK Chitra heart valve prosthesis (chvp), a tilting disc mechanical heart valve of low cost and proven efficacy, has been in use for the last 15 years in India. Although various studies substantiating its long-term safety and efficacy are available but is less commonly used in Nepal. The TTK Chitra heart valve has been developed and widely used in India.

Keywords: TTK Chitra valve, efficacy, Rheumatic heart disease

INTRODUCTION

29 TTK Chitra valve:

TTK CHITRA VALVE



TTK CHITRA HEART VALVE PROSTHESIS (CHVP) IS A TILTING DISC ARTIFICIAL HEART VALVE DESIGNED AND DEVELOPED BY SREE CHITRA TIRUNAL INSTITUTE FOR MEDICAL SCIENCES AND TECHNOLOGY (SCTIMST).

In Nepal, large numbers of people suffer from heart valve damage as a result of rheumatic heart disease. This condition is produced when some bacterial throat

infections, especially in children, evoke a severe immune response known as rheumatic fever¹. Without valve replacement patients with rheumatic heart disease are at risk of heart failure and death. The Indian council of medical research has estimated that six out of every 1,000 children between the ages of five and fifteen in the country suffer from rheumatic fever². Over one million children in the country could therefore be at risk of developing valvular disease.

TTK chitra heart valve prosthesis (chvp) is a tilting disc artificial heart valve designed and developed by sree chitra tirunal institute for medical sciences and technology (sctimst)^{3,4}. It has an ultra-high-molecular-weight polyethylene disc, haynes-25 alloy (haynes international inc., usa) cage, and polyester suture ring. Since its first implant on 6 December 1990, more than 15,000 valves have been implanted in various institutions in India. Because of its low cost and proven efficacy, it has a high potential for more widespread use in developed countries.

CASE HISTORY

A patient was a 42-year-old female. At 34 years of age, she complained of nasal bleed and epistaxis in B&C medical



©Authors retain copyright and grant the journal right of first publication. Licensed under Creative Commons Attribution License CC - BY 4.0 which permits others to use, distribute and reproduce in any medium, provided the original work is properly cited.

*Corresponding Author:

Umesh Yadav

Email: umy492006@yahoo.com

ORCID: <https://orcid.org/0000-001-8202-8733>

Citation

Kumar V, Yadav U, Kumar A, V, The Mechanical Heart Valve TTK Chitra is Inexpensive and of Proven Effectiveness (widely Used In India and then in Nepal), MJEN. 2022 June; 1(1): 42-44.



college teaching hospital. she was diagnosed with severe mitral stenosis at B&C medical college and teaching hospital, Jhapa birtamode, Nepal with hemodynamically unstable. The patient was further referred for Percutaneous transvenous mitral commissurotomy in the year of 2019 in Nepal. Her symptoms were not improved and she underwent mitral valve replacement with 29tk chitra valve was done at 2021. Previous echo report at B&C teaching hospital shows: thickened fibrotic mv with calcium specks, mva-07 cm trivial mitral regurgitation (partially), La 5.7cm, mv gradient 16/10mmhg, mitral valve annulus 3.20 aortic valve (vid 4/2.6 cm, trivial tricuspid regurgitation, rvsp-45mmhg, no La/Laa clot, normal biventricular function Ef 65%. The patient was under medication: atenolol 25 mg, Lasix20mg, and acitrom 4mg.

ECHOCARDIOGRAPHY IN B&C Medical College Teaching Hospital IN THE YEAR OF 2019

Pre status echo at B&C Medical College Teaching Hospital

Rheumatic heart disease: Severe MS, Mvoa by planimetry was 0.7cm^2 Mean gradient 8 mmhg, peak gradient 16 mmhg. Dilated La, No La or Laa clot. Normal biventricular function.

Figure 1:

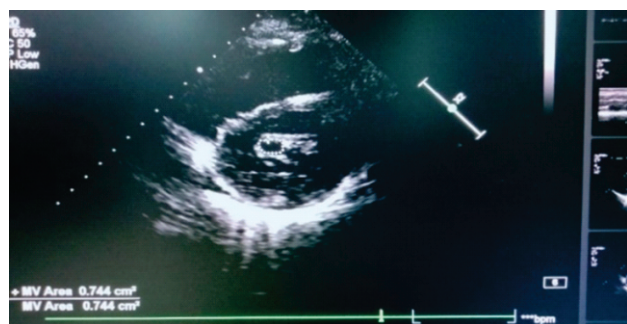


Figure 2:

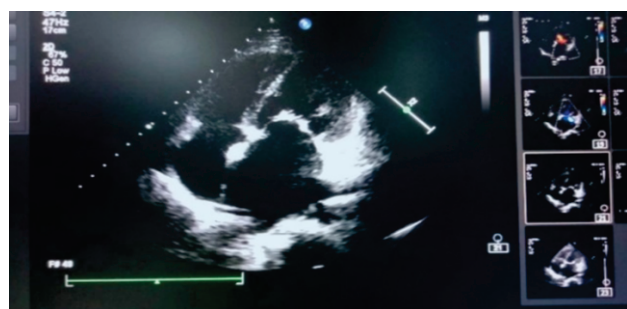
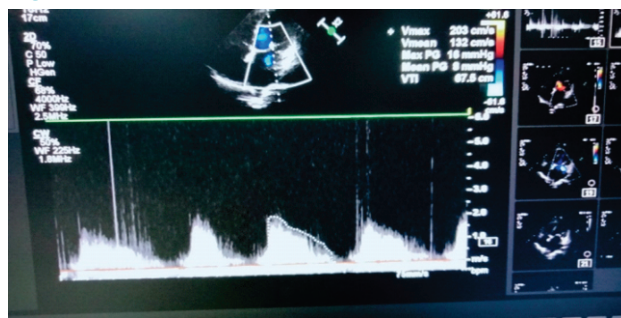


Figure 3:

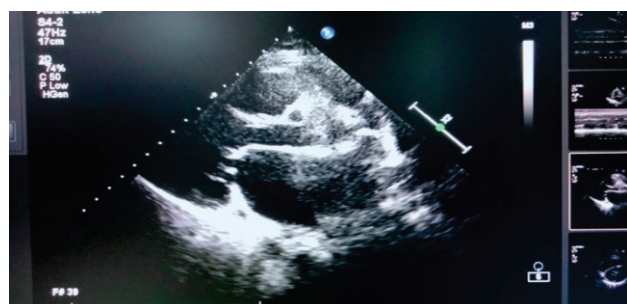

Figure 4:



Post status: mvr(normal functioning prosthetic valve mean gradient 10mmhg and peak gradient 17mmhg,AML&PML prosthetic, Dilated la.

Figure 1:

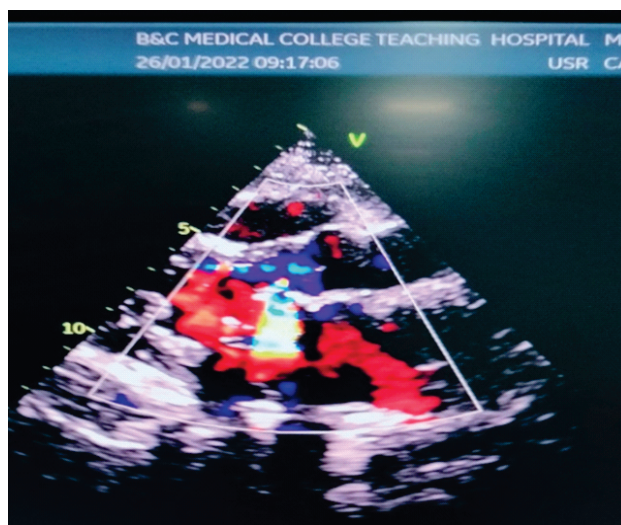
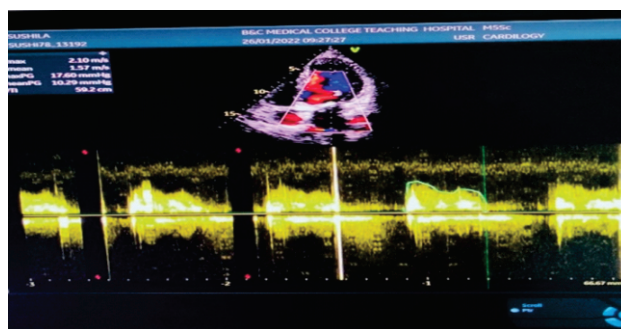


Figure 2:

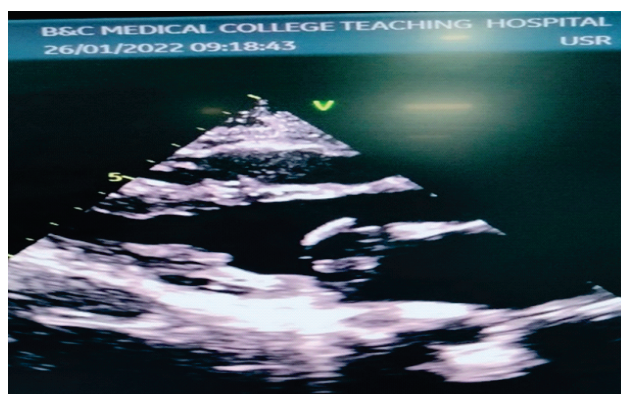

Figure 3:



DISCUSSION

The rheumatic disease continues to be a major indication for valvular heart surgery in Nepal and India. Most commonly used for replacement are mechanical heart valves and biological valves. Chitra heart valve prosthesis (chvp), a tilting-disc valve developed by scimst, Kerala, has gained immense popularity in developing countries because of its low cost, high quality, and durability⁴. Thousands of patients with valvular heart diseases have been benefited after the implantation of chitra valves. previous have demonstrated a proven clinical efficacy of the chvp in the postoperative follow-up studies⁵. The doppler parameters obtained with a chvp in the mitral and aortic position are comparable with those obtained with the different tilting-disc prosthetic valves in common use⁶. The TTK Chitra mechanical heart valve is being widely used in India. We present a hemodynamic study of this valve implanted in the mitral and aortic positions. The TTK Chitra valve is hemodynamically comparable to other mechanical valves. It has a high potential for more widespread use in India and developing countries. The TTKChitra mechanical valve reported hemodynamics, complications, and event-free survival in comparison with other commonly used prosthetic valves. Patients who had undergone TTK Chitra valve replacement either in mitral and aortic position or both and will undergo routine follow-up in Cardiothoracic surgery OPD and have been subjected to a routine follow-up echocardiographic examination.

CONCLUSION

Patients suffering from significant cardiac valvular lesions, an intervention on the valve with repair, valvuloplasty, or replacement may be necessary. Although for mitral and tricuspid regurgitant lesions valve repair is frequently performed, valve replacement remains a common choice

for many adult (many adult) patients. TTKChitra valve is hemodynamically stable and affordable and performs well in both the mitral and aortic valve positions for low socioeconomic status patients.

Funding: None

Conflict approval: None

Ethical approval: Yes

REFERENCES

- [1] Carapetis JR, Steer AC, Mulholland EK, Weber M. The global burden of group A streptococcal diseases. *The Lancet Infectious Diseases*. 2005;5(11):685-94. PMID: 16253886
- [2] Negi PC, Sondhi S, Asotra S, Mahajan K, Mehta A. Current status of rheumatic heart disease in India. *Indian Heart J*. 2019;71(1):85-90. doi:10.1016/j.ihj.2018.12.007
- [3] Bhuvaneshwar GS, Muraleedharan CV, Vijayan GA, Kumar RS, Valiathan MS. Development of the Chitra tilting disc heart valve prosthesis. *The Journal of Heart Valve Disease*. 1996 Jul;5(4):448-458. PMID: 8858513.
- [4] Sankarkumar R, Bhuvaneshwar GS, Magotra R, Muralidharan S, Rajan RS, Saha D, Subba Rao KS, Valiathan MS, Radhakrishna S, Ramani AV. Chitra heart valve: results of a multicenter clinical study. *J Heart Valve Dis*. 2001 Sep;10(5):619-27. PMID: 11603602.
- [5] Malhotra A, Pawar SR, Srivastava A, Yadav BS, Kaushal R, Sharma P, Songra M. Clinical and hemodynamic study of tilting disc heart valve: Single-center study. *Asian Cardiovasc Thorac Ann*. 2014 Jun;22(5):519-25. DOI:10.1177/0218492313475640. Epub 2014 Mar 19. PMID: 24646514.
- [6] Namboodiri N, Shajeem O, Tharakan JA, Sankarkumar R, Titus T, Valaparambil A, Sivasankaran S, Krishnamoorthy KM, Harikrishnan SP, Dora SK. Doppler echocardiographic assessment of TTK Chitra prosthetic heart valve in the mitral position. *Eur J Echocardiogr*. 2008 Sep;9(5):599-604. DOI: 10.1093/ejechocard/jen001. Epub 2008 Feb 12. PMID: 18296411.